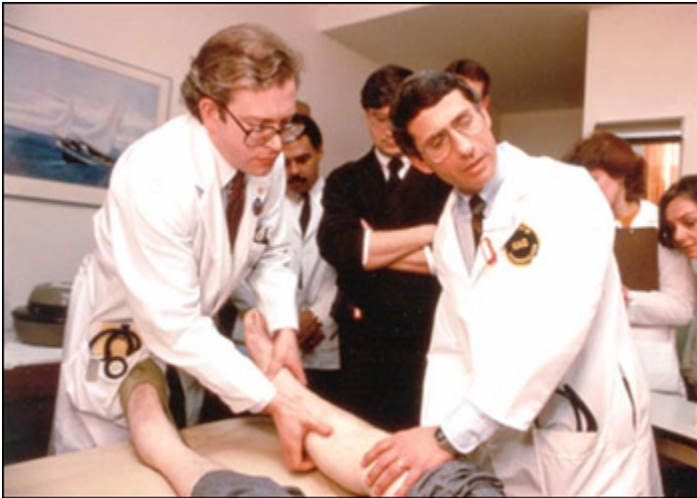
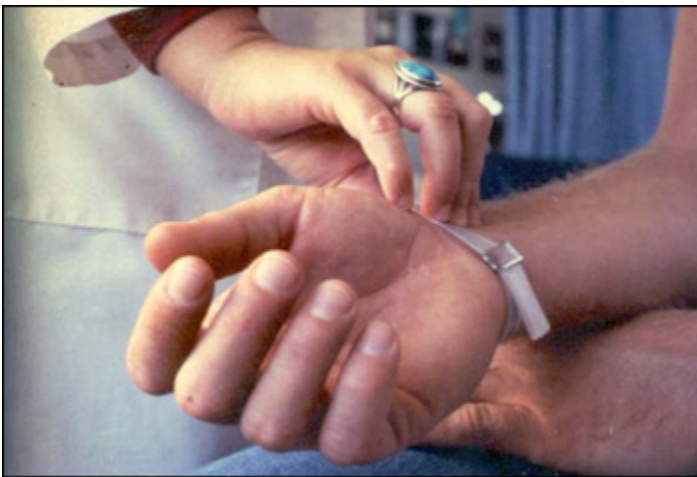

Clinical Images

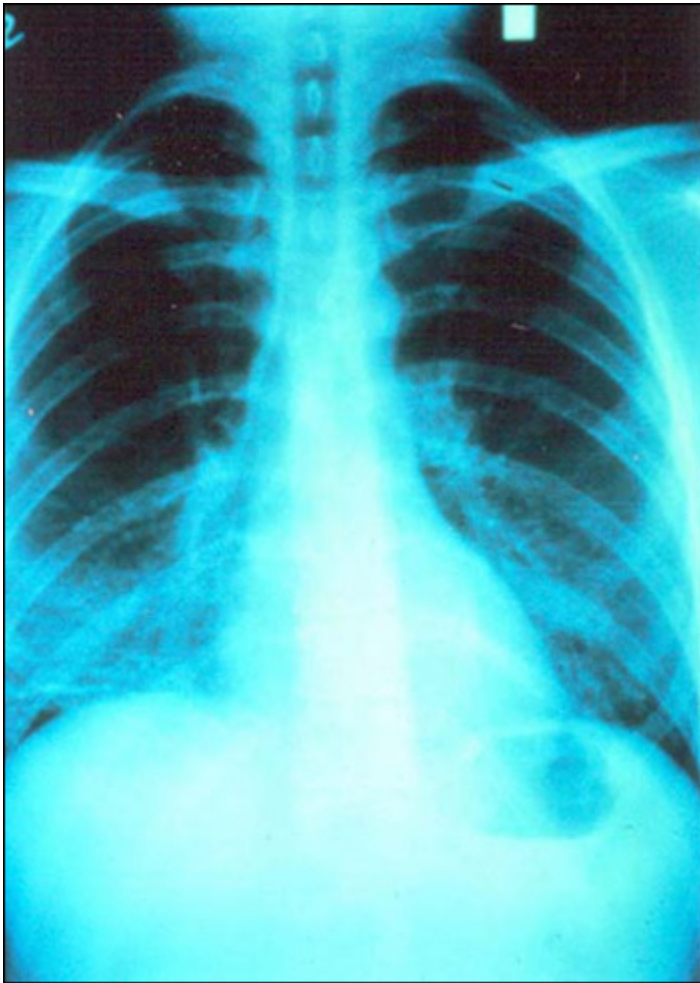
Clinical Images



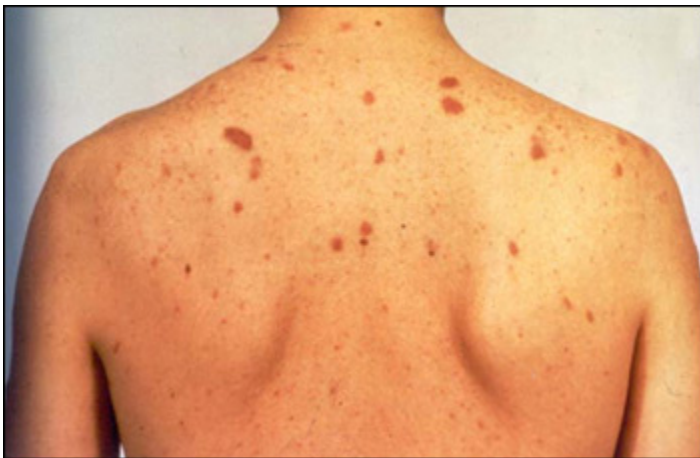Drs. Lee Hall and Anthony S. Fauci examine participant in early AIDS study.



Healthcare worker takes a patient's pulse.



An x-ray of a lung showing infection with *Pneumocystis carinii* pneumonia.



A person's back with purplish lesions of Kaposi's sarcoma.
The purplish lesions of Kaposi's sarcoma, a cancer not usually seen in young men, were common among the patients with the new immune deficiency disease